

# Splenic Hydatid Cyst Attacking Retroperitoneum

## Retroperitonu Tutan Dalak Kist Hidatiği

Bülent KAYA, Yalım UÇTUM, Rıza KUTANIŞ

Department of General Surgery, Vakıf Gureba Education and Research Hospital, Istanbul, Turkey

### ABSTRACT

Hydatid disease most commonly affects the liver and lungs but no organ is immune. Splenic hydatid cyst is a rare clinical entity. Although the patients are usually asymptomatic, the disease may present with secondary infection, adhesion to adjacent organs with fistulisation or rupture into abdominal cavity. We present a 67 year old woman with splenic hydatid cyst. Severe adhesions and tumorlike growth were found in the retroperitoneal region. To our knowledge, retroperitoneal invasion with a splenic hydatid cyst is a very rare clinical condition. Total splenectomy was performed without complication. (*Türkiye Parazitol Derg* 2010; 34: 193-5)

**Key Words:** Spleen, hydatid cyst, retroperitoneum

**Received:** 03.05.2010

**Accepted:** 24.11.2010

### ÖZET

Kist hidatik en sık akciğer ve karaciğeri etkilerken diğer organlar bağışıklık kazanmış değildir. Dalakda kist hidatik nadir görülen klinik bir durumdur. Genellikle hastalar asemptomatik olmakla beraber hastalık, sekonder enfeksiyonlar, çevre organlara yapışma, fistülizasyon ve karın içine rüptür ile seyredebilir. Dalak kist hidatiği olan 67 yaşında hastayı sunuyoruz. Retroperitoneal bölge, tümör benzeri büyüyen kitle ve yapışıklıklarla invaze edilmişti. Bildiğimiz kadarı ile dalak kist hidatiğinin retroperitoneal bölge invazyonu çok nadir görülen klinik bir durumdur. Total splenektomi komplikasyon olmaksızın uygulandı. (*Türkiye Parazitol Derg* 2010; 34: 193-5)

**Anahtar Sözcükler:** Dalak, kist hidatik, retroperiton

**Geliş Tarihi:** 03.05.2010

**Kabul Tarihi:** 24.11.2010

### INTRODUCTION

Hydatid disease, also called *Echinococcosis* is caused by the larval form of parasites of the genus *Echinococcus*. Humans are the accidental intermediate host. It is an endemic disease in the Middle East, North Africa, New Zealand, Australia, and South America. Although hydatid disease can be found in any organ or soft tissue, it most frequently affects the liver and lungs (1).

Splenic hydatid cyst was first described as an autopsy finding in 1790 by Berlot (2). Splenic involvement is rare, and has

been detected in about 0.5-4% of all patients with hydatid disease (3). Some complications may be seen with splenic hydatid cyst such as secondary infection, fistulisation to adjacent organs and rupture into the peritoneal cavity. Systemic anaphylactic reaction is a life-threatening complication of ruptured hydatid cyst.

We describe a splenic hydatid cyst attacking the retroperitoneal region with severe adhesions. Splenectomy was performed without complication.

## CASE REPORT

A 67 year old woman presented with abdominal discomfort and nausea of one year duration. She had no history of abdominal or lumbar pain and her past medical history was unremarkable. Physical examination showed palpable masses in the right and left upper abdominal quadrants.

Routine laboratory tests were within normal limits including hemoglobin and hematocrit levels, leucocyte count, renal and liver function tests and chest roentgenogram.

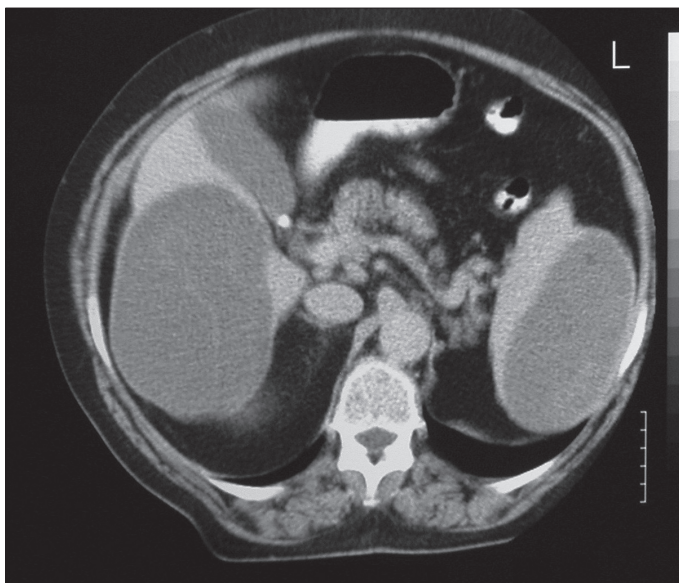
Abdominal computed tomography revealed a splenic cyst measuring 125x65 mm and a liver cyst measuring 140x80 mm (Figure 1). The lesions had characteristic appearance of a hydatid cyst. Laparotomy was performed through a midline incision. Surgical exploration revealed a huge hydatid cyst in the right lobe of the liver measuring approximately 150x80 mm and a hydatid cyst in the posterior part of the spleen measuring approximately 130x70 mm. Adhesions between the splenic hydatid cyst and omentum were noted. The cyst was infiltrating the retroperitoneum posteriorly. The omental adhesions were dissected.

Retroperitoneal adhesions were excised with Gareto's fascia of the left kidney. The lesion was near the renal artery and vein. The cyst was resected en-bloc with the spleen (Figure 2, 3). Partial cystectomy was performed for the hydatid cyst in the liver. Pathological examination of the resected specimen confirmed the diagnosis of splenic hydatid disease.

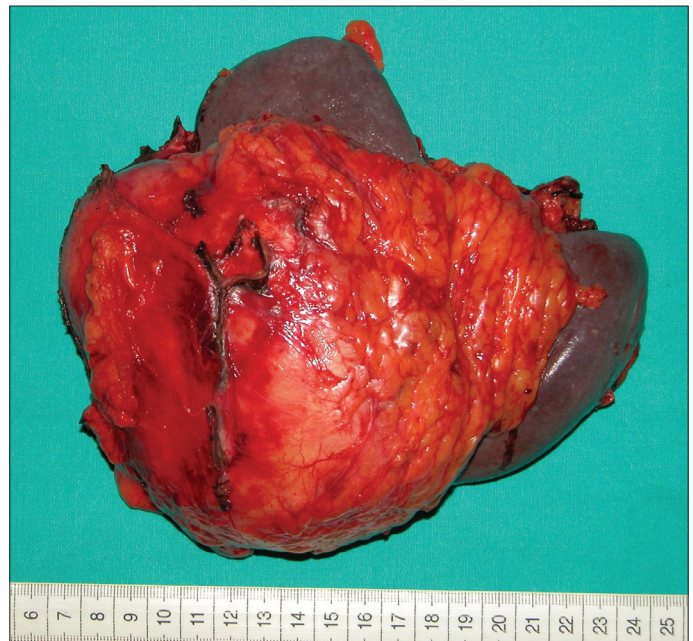The postoperative period was uneventful. She was discharged on the seventh postoperative day with albendazole (10 mg/kg/day) therapy.

## DISCUSSION

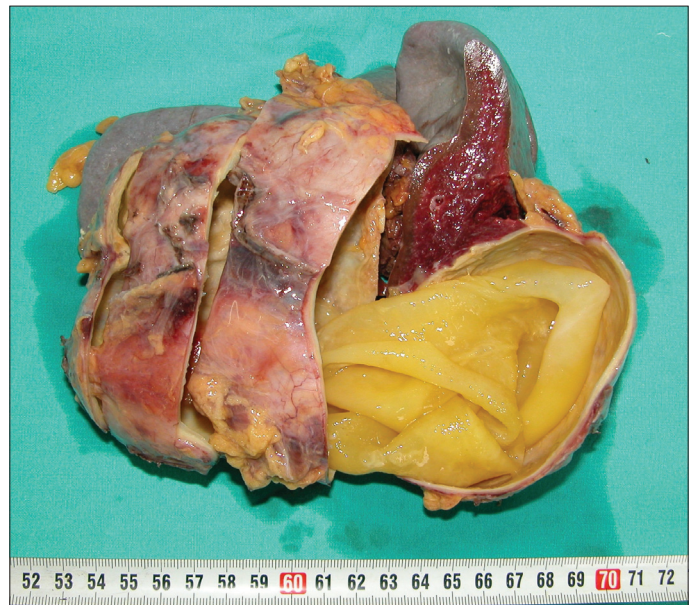
Hydatid disease is still an important health problem worldwide. Involvement of the spleen by *Echinococcus* is an uncommon event because cyst embryos are trapped in the liver and lungs, with only 15% entering systemic circulation. It is the eggs of parasite which



**Figure 1.** Hydatid cysts in liver and spleen in abdominal computed tomography



**Figure 2.** Hydatid cyst in posterior part of the spleen



**Figure 3.** Hydatid membranes on pathological examination

escape the liver-lung barrier and cause splenic infection (4). Splenic hydatid disease may also arise with retrograde spread of parasites via the portal and splenic veins or intraperitoneal rupture of a hepatic hydatid cyst.

Most of the patients with splenic hydatid cyst are asymptomatic and the diagnosis is incidental. The cysts are usually solitary and grow slowly. The main symptoms associated with the disease are abdominal discomfort, pain and palpable mass in the left upper quadrant. Tarcoveanu E. reported 38 cases of splenic *Echinococcosis* and abdominal pain was the most common symptom among these patients (5).

Ultrasonography and computed tomography are the major diagnostic tools for splenic hydatid cyst. Hydatid cyst must be

differentiated from cystic neoplasms such as lymphangioma and haemangioma, epidermoid cyst and post-traumatic pseudocyst (6). Calcification of the cyst wall, presence of daughter cysts, cystic membranes, septa or hydatid sand are all imaging findings that support the diagnosis of splenic hydatid disease. These findings are not always present and especially not detected in the early stages of the disease. Magnetic resonance has a role in complicated splenic hydatid cysts but it should not be used as the first imaging method. Serological tests are highly sensitive and specific for *Echinococcosis*. Today, the correct diagnosis of splenic hydatid cyst can be made with a combination of radiological and serological tests in 90% of cases (7).

Splenic hydatid cyst may cause different complications. Secondary infection of a hydatid cyst, fistulisation to adjacent organs or intraabdominal rupture are the main complications. Chronic pericystic inflammation may cause adhesions with nearby organs such as the kidney, left diaphragm, colon, stomach. The growing cyst can adhere and erode the diaphragm and intestinal wall and cause fistula formation. Teke et al. (8) reported a splenic hydatid cyst perforating into the left colon and causing massive gastrointestinal bleeding. The splenic hydatid lesions may exhibit tumourlike growth and metastasise to intra or retroperitoneal organs. The splenic cyst was penetrating into the retroperitoneum posteriorly in our case. Gerota's fascia of the kidney was infiltrated with pericystic inflammation. The curative resection was very difficult. The anatomical relations of splenic hydatid cyst should be demonstrated before surgery.

Different surgical techniques are used to treat splenic hydatid disease. Total splenectomy, partial splenectomy, cyst enucleation and unroofing with omentoplasty are the most commonly preferred methods (9, 10). The splenic cyst with adhesions or infiltrations to nearby organ should be treated by total splenectomy. However, if the splenic cyst has metastatic implantations to adjacent organs where safe resection is impossible, it can be treated with conservative surgical techniques such as partial splenectomy and omentoplasty.

## CONCLUSION

In summary, this case demonstrates that some splenic hydatid cysts may cause formation of serious adhesions to adherent organs, including the retroperitoneum. The splenic hydatid cyst may become a challenging surgical problem. Preoperative evaluation should be carried out carefully.

## Conflict of Interest

No conflict of interest was declared by the authors.

## REFERENCES

1. Franquet T, Montes M, Lecumberri FJ, Esparza J, Bescos JM. Hydatid disease of the spleen: Imaging findings in nine patients. *AJR Am J Roentgenol*, 1990; 154: 525-8.
2. Muro J, Ortiz-Vazquez J, Mino G, Sanmartin P. Demonstration angiografica del quiste hidatidico de bazo. *Rev Clin Esp*, 1969; 115: 433-8.
3. Munzer D. New perspectives in the diagnosis of echinococcus disease. *J Clin Gastroenterol*, 1991; 13: 415-23.
4. Soler-Bechara J, Sascia JL. Calcified echinococcal cyst of the spleen. *JAMA*, 1964; 187: 62-3.
5. Tarcoveanu E, Pleşa A, Danila N, Lupaşcu C, Cotea E, Negru R. Splenic hydatid cyst. Observations upon 38 cases of splenic echinococcosis. *Rev Med Chir Soc Med Nat Iasi*, 2002; 107: 311-5.
6. Husen YA, Nadeem N, Alsam F, Bhaila I. Primary splenic hydatid cyst: a case report with characteristic imaging appearance. *J Pak Med Assoc*, 2005; 55: 219-21.
7. Kune GA, Morris DL. Hydatid disease. In Schwartz SI, Ellis H, (eds). *Maingot's abdominal operations*. London: Appleton Lange, 1990, pp.1225-40.
8. Teke Z, Yagci A B, Atalay A O, Kabay B. Splenic hydatid cyst perforating into the colon manifesting as massive lower gastrointestinal bleeding : an unusual presentation of disseminated abdominal echinococcosis. *Singapore Med J*, 2008; 49: 113-6.
9. Amatidis K, Papaziogas B, Mirelis C, Pavlidis T, Papaziogas T. Splenectomy versus spleen-preserving surgery for splenic echinococcosis. *Dig Surg*, 2003; 20: 527-31.
10. Berrada S, Ridai M, Mokhtari M. Hydatid cysts of the spleen. splenectomy or conservative surgery? *Ann Chir*, 1991; 45: 434-6.